

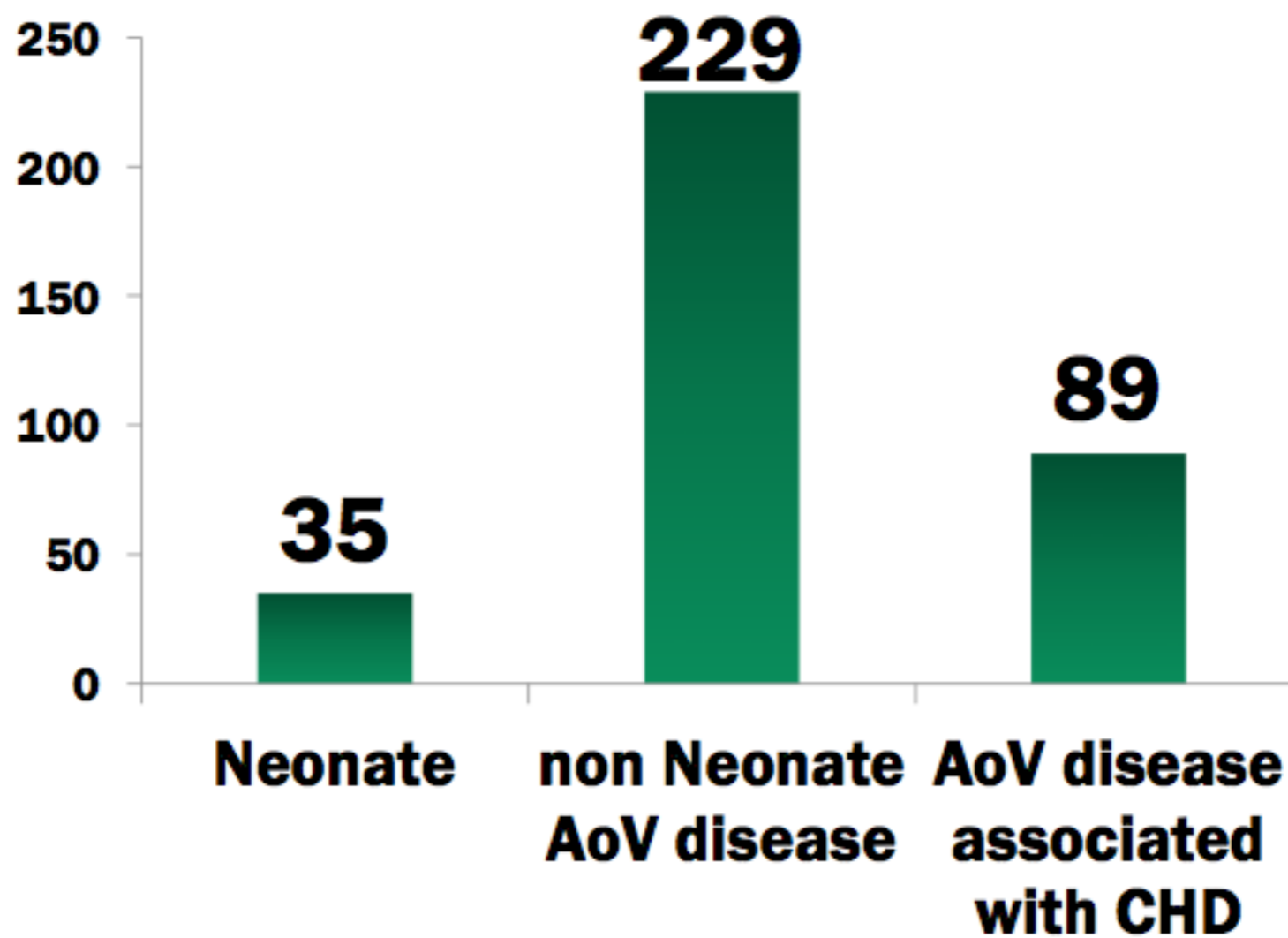
# **Aortic valve repair including replacement of the right coronary leaflet with the Matrix Patch equine**

*Prof. Dr. B. Asfour*

**Director  
German Pediatric Heart Center  
Sankt Augustin**



## AoV repair procedures 2003-2016

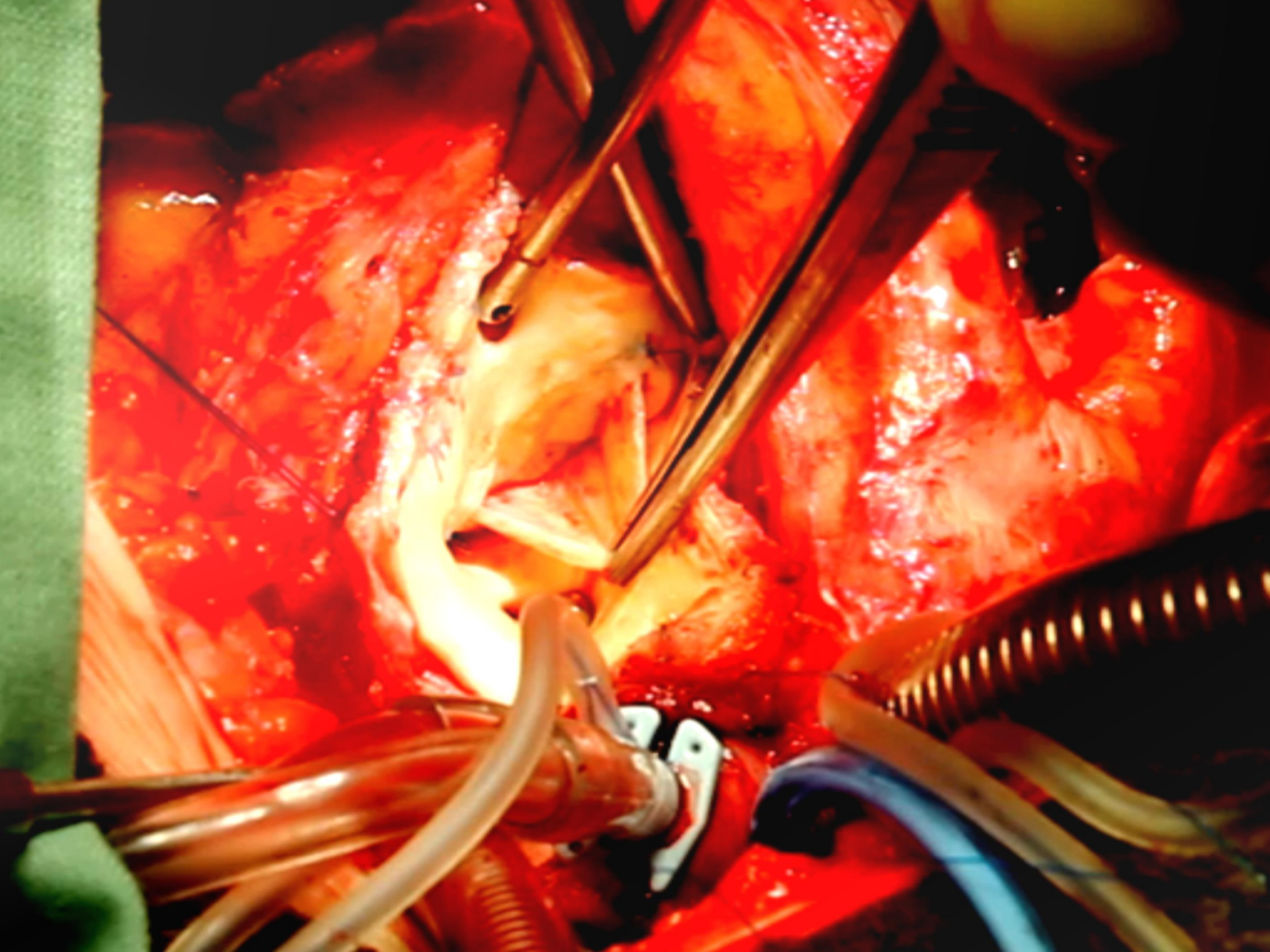


## Casereport: Newborn aortic stenosis

---

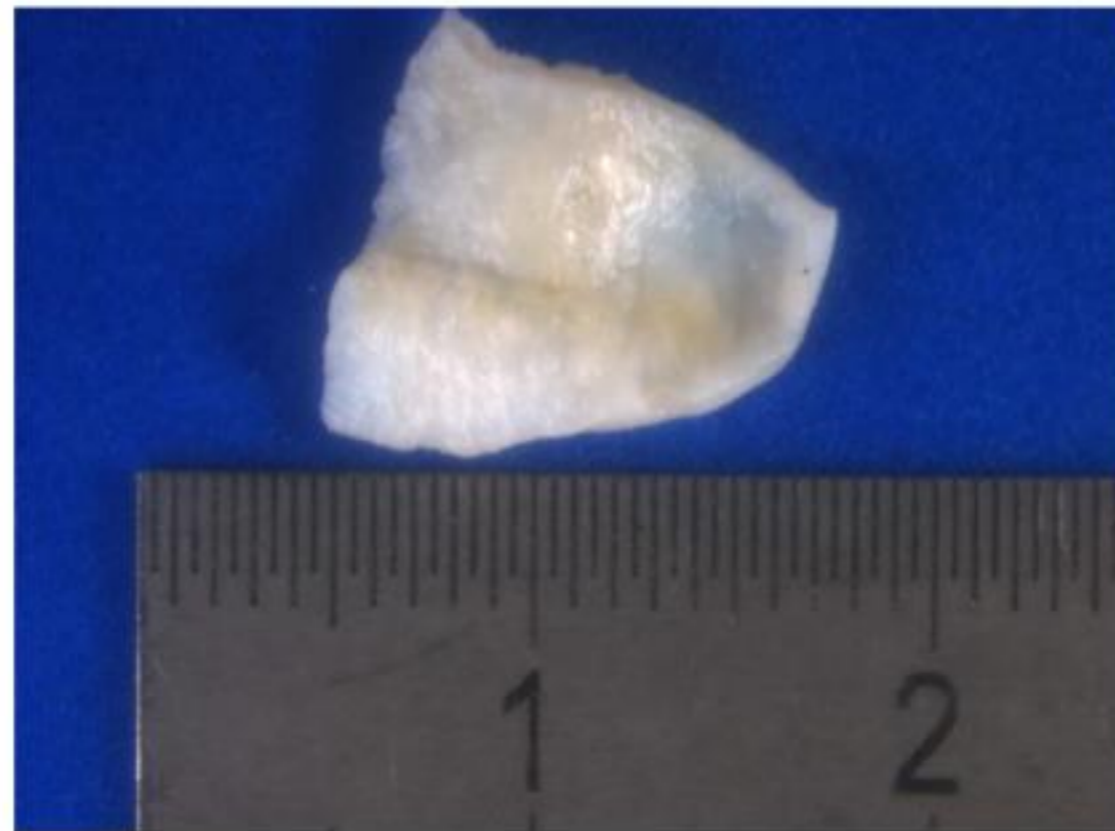
- **Ballon valvoplasty =>** **May 2005**
- **Aortic valve repair =>** **Oct. 2006 (Video)**
  - Replacement RCL by autol. pericard
- **Redo AvR=>** **Sept. 2012 (Video)**
  - Replacement of RCL by Matrix ®
- **Aortic valve replacement (On-X 21mm)** **Sept. 2017 (Video)**



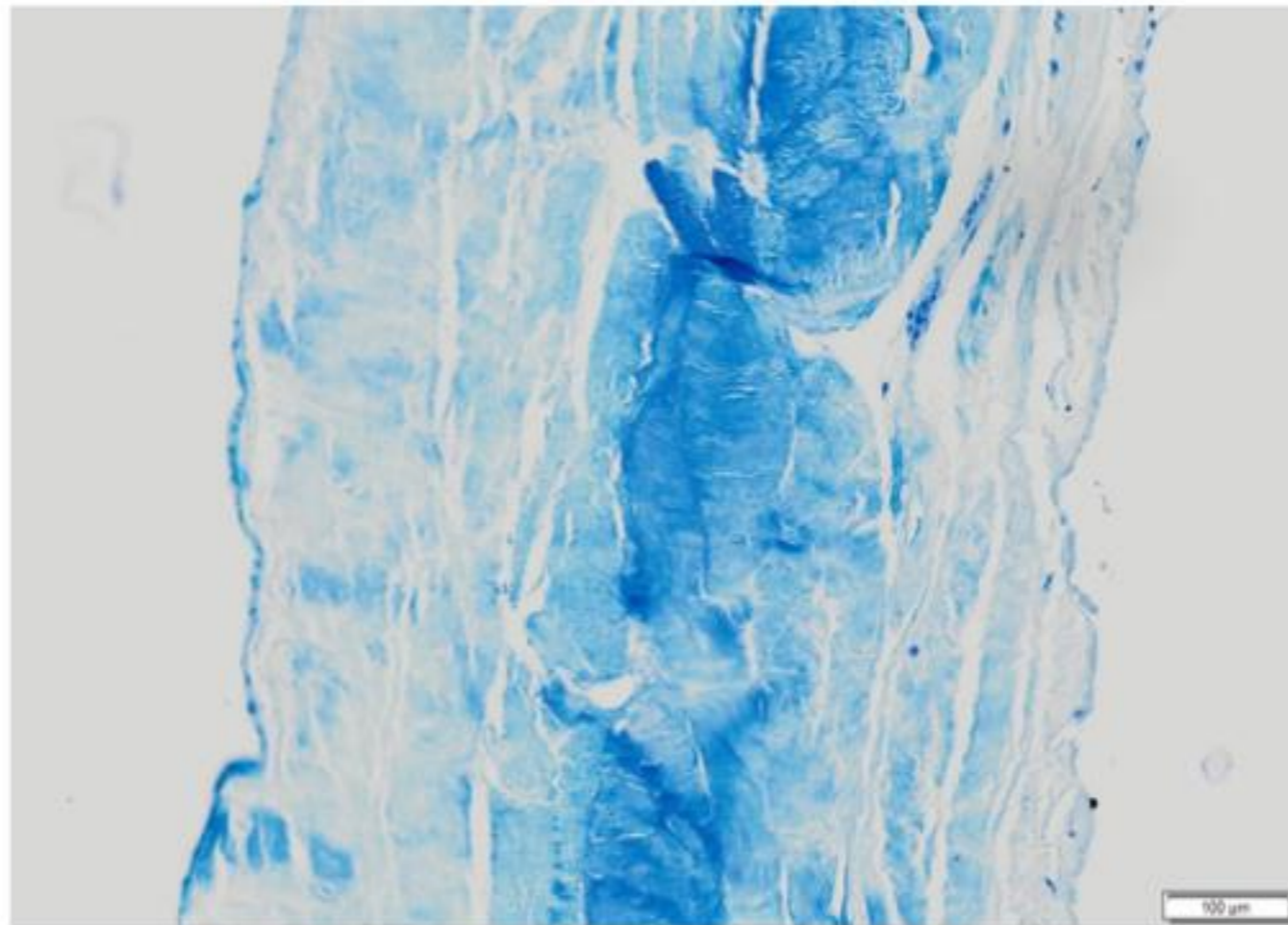


# Histology

---



# Histology



# Histology



## Conclusion

---

- **Aortic valve repair is palliative in most cases**
- **Surgical repair has superior results compared to balloon valvoplasty**
- **Results after valve replacement (autol. pericard) in "young" patients is inferior to simple techniques**
  - Autotissue® advantage?
- **Results after valve replacement in "older" patients is superior**
  - autol. pericard in newborns lasts 2-3y
- **Autotissue® leaflet replacement has shown in a growing child (7y =>12 y)**
  - no calcification
  - endothelial lining
  - ....



